

Management of minor to moderate head trauma in children - Guidelines of the Polish Association of Paediatric Surgeons

Management of minor to moderate head trauma in children - Guidelines of the Polish Association of Paediatric Surgeons

Grażyna Skotnicka-Klonowicz*, Jan Godziński, Adam Hermanowicz, Jan Wendland, Erwin Strzesak, Krzysztof Strzyżewski, Piotr Czauderna

* On behalf of the team formed by the Central Administration of the Polish Association of Paediatric Surgeons - the Teaching Department of Paediatric Emergency Medicine, the "Maria Konopnicka" Teaching Hospital no. 4, Medical University in Lodz

Standardy Medyczne/Problemy Chirurgii Dziecięcej ■ 2014 ■ vol. 4 ■ 42-50

Assumption:

1st Head injuries are a reason for 1/3 of ER admissions of children who sustained a trauma. For example, based on the experience of the Teaching Department of Paediatric Emergency Medicine at the "Maria Konopnicka" Teaching Hospital no. 4 in Lodz, 24.7% of all admitted children had a head injury.

2nd There is no clear definition of a minor head injury, and there are numerous classification criteria for a trauma to the head¹⁻⁶.

3rd Results of a survey completed among paediatric surgeons in Poland indicated a significant variability of management protocols in case of minor and moderate head injuries⁷. Controversies were associated with the type of imaging diagnostics techniques (X-ray vs. CT), indications for imaging diagnostics and for hospitalisation. Absence of management principles for children who sustained moderate and minor trauma to their head is also underlined by foreign researchers^{4,6,8-10}.

Based on the Glasgow Coma Scale (GCS) introduced 40 years ago, and its modification for young children, head injuries are divided into minor (score ≥ 13), moderate (score 12-9) and severe (≤ 8). Using that classification, the course of diagnostics of a child with a severe or moderate head injury should clearly involve: hospitalisation, imaging diagnostics, neurological, and ophthalmological examination²⁻¹².

On the other hand, in the case of a child with a minor head injury the course of action is not so clear, as this group is the most variable one, and the rate of complications requiring a neurosurgical intervention may reach as much as 83%.¹³

A minor head injury is defined differently by the American Academy of Pediatrics. According to their definition, minor head injury is a trauma that caused no loss of consciousness or the loss of consciousness lasted less than 1 minute, the GCS score at the first examination was 15, a neurological examination determined no deviations from the normal, and no clinical signs of cranial bone fractures were found. Children may present the following symptoms: vomiting, headache, and drowsiness. The risk of intracranial complications in the above group is less than 1:5 000.

Stein and Doolin discriminate between a minor and a minimal head injury, whereas the latter is defined as: a condition free from any neurological deviations from the normal, consciousness scored GCS 15, no retrograde amnesia or external signs of trauma.¹³

Based on their experience in treatment of head injuries in children at the Paediatric Neurosurgery Ward of the University Paediatric Hospital in Krakow, Kwiatkowski *et al.* suggested determination of a type of diagnostic procedures based on the risk of head injury, defined in the following way:

High risk - GCS 13-12; GCS score reduction by 2 points during the observation; Convulsions; Meningeal signs; Focal signs; Subgaleal haematoma; Palpable cranial indentation; Open trauma to the head; History of haematological conditions, radiotherapy and chemotherapy.

Medium risk - GCS - 14; Loss of consciousness >1 minute; Drowsiness; Headaches; Vomiting > 3 times; Retrograde amnesia; History of convulsions; Multiple trauma; Injury of the facial skeleton, and also suspicion of abuse; Neonate or infant < 6 months of age.

Low risk - GCS - 15; Low-energy trauma, No loss of consciousness and no history of retrograde amnesia; Vomiting less than 3 times; No positive meningeal signs; No sign of a local trauma¹².

Based on the current national and international algorithms and guidelines of management of a child with a head injury, the Polish Association of Paediatric Surgeons suggests as follows:

- 1st To adopt the definition of a minor isolated head injury suggested by the American Academy of Pediatrics (The Committee on Quality Improvement).
- 2nd To maintain the Glasgow Coma Scale as a tool for assessment of the consciousness level and monitoring of changes of child's neurological condition after a trauma, and to adopt the modified Glasgow score for young children under the age of 3 years (**Appendix 1**).
- 3rd To modify and clarify the risk scale suggested by Kwiatkowski et al. for diagnostic and therapeutic procedures in children with minor and moderate head injury. The modification involves incorporation of children with co-existing multiple injury and children who fell from the height of over 60 cm to the group of "high risk;" and to incorporate children injured in traffic accidents, hit by a moving vehicle or object, children who fell from the height of over 30 cm, children who sustained a trauma in unknown circumstances, children with mental handicap, children with limited contact because of their principal disease (CP, autism, etc.), and children remaining in a foster home or whose contact with parents is limited because of other reasons, to the group of medium risk (the modified scale is provided below):

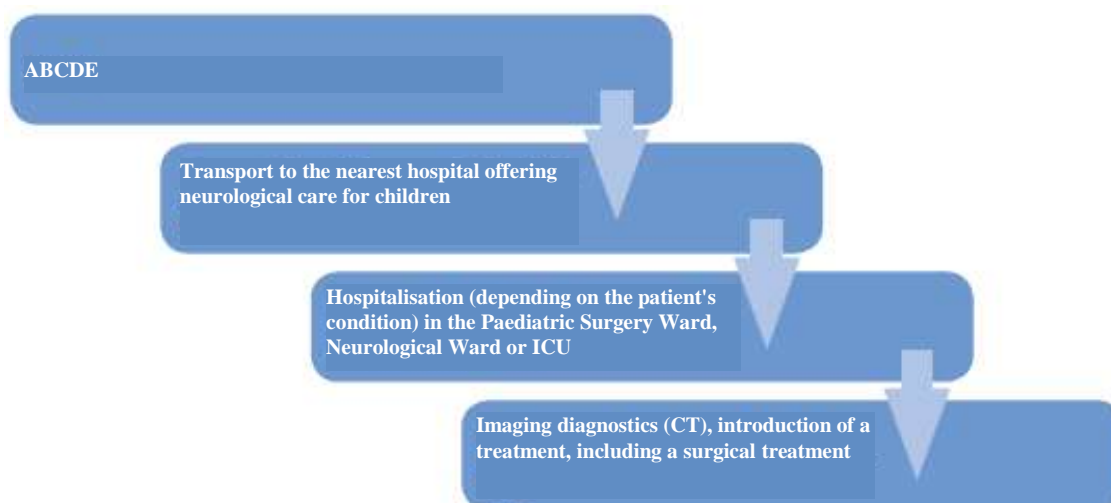
High risk - GCS 13-12; GCS score reduction by 2 points during the observation; Convulsions; Meningeal signs; Focal signs of CNS injury; Subgaleal haematoma; Palpable cranial indentation; Open trauma to the head; Fall from the height of >60 cm; History of haematological conditions, radiotherapy and chemotherapy. Coexistence of a multiple organ injury.

Medium risk - GCS - 14; Loss of consciousness > 1 minutes; Drowsiness; Headaches; Vomiting > 3 times; Retrograde amnesia; History of convulsions; Multiple site injury; Trauma to the facial skeleton, Suspicion of abuse; Neonate or infant

<6 months of age; Traffic accident, hit by a moving vehicle, hit by a moving object, fall from the height of over 30 cm but less than 60 cm, an injury sustained in unknown circumstances, an injury in a mentally handicapped child, in a child with limited contact because of a principal disease (CP, autism, etc.), in a child remaining in a foster home or whose contact with parents is hindered because of other reasons.

Low risk - GCS - 15; Low-energy trauma, No loss of consciousness and no history of retrograde amnesia; Vomiting less than 3 times; No positive meningeal signs; No sign of a local trauma⁴⁻¹⁷.

- 4th Considering emerging reports regarding a possible detection of intracranial haemorrhage with a portable near infrared spectroscope, in children over 3 years of age and meeting the qualification criteria, to introduce the Infrascanner examination to the diagnostics of minor to moderate head injuries¹⁸⁻²⁰ (**Appendix 2**).



Scheme 1. Diagnostic and therapeutic procedures for head injury in HIGH RISK children (regardless the child's age)

Diagnostic and therapeutic procedures in head injuries in children

I. High risk (regardless the child's age)

- Scheme 1.

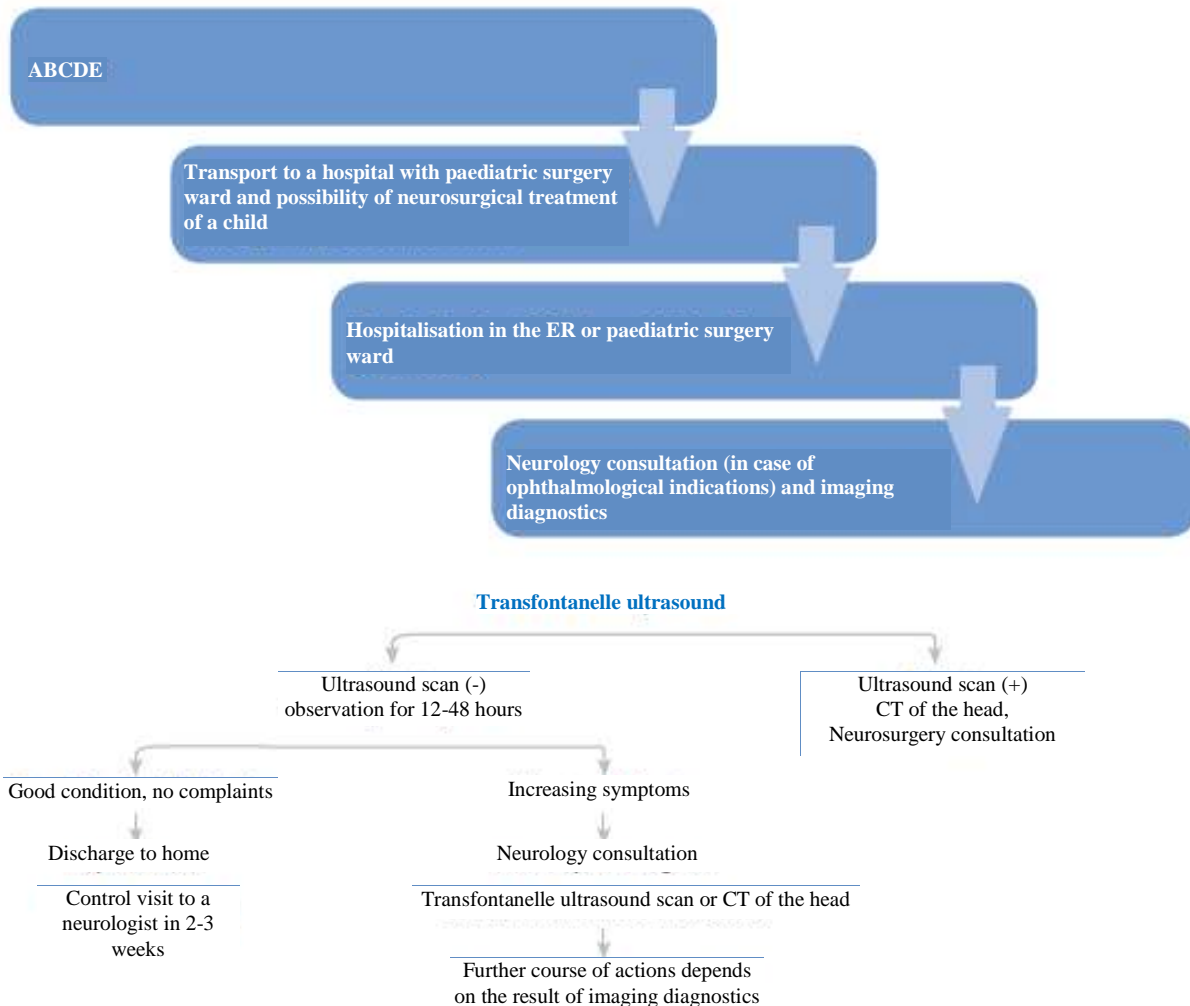
1. Assessment and management of basic life functions (ABCDE).
2. Transport to the nearest hospital with a paediatric neurosurgery ward or a neurosurgery ward able to accept a child - reduction of time between the trauma to the head and onset of high specialised therapy and reduction of healthcare costs
3. Admission to the ward (depending on the child's condition - paediatric surgery, neurosurgery, ICU), imaging diagnostics and neurological assessment and possibly a neurosurgical assessment, possible introduction of a treatment, including a surgical treatment.

II. Medium risk (regardless the age)

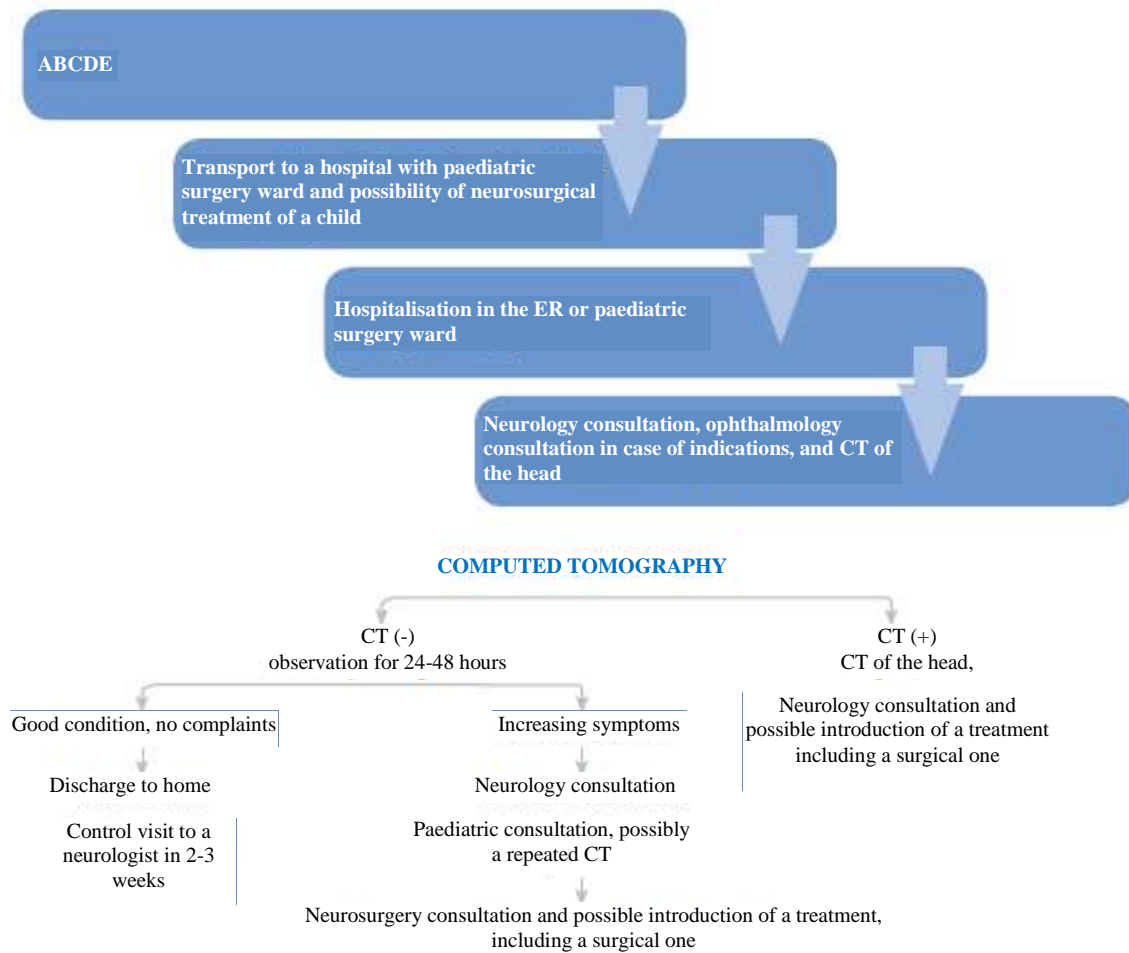
- 1st Assessment and management of basic life functions (ABCDE).
- 2nd Transport to the nearest hospital with paediatric surgery ward and a possible neurosurgical treatment, if need be.
- 3rd Medical examination (including a precise history of the accident, the child's behaviour after the accident, and medical history of the child), neurology and ophthalmology consultation at the ER or paediatric surgery ward, imaging diagnostics.

In case of a child under 1 year of age, with non-fused fontanels - Scheme 2a

- Transfontanelle ultrasound scan
- Result of the ultrasound scan (-) - inpatient observation



Scheme 2a. Scheme of diagnostic and therapeutic procedures for head injury in MEDIUM RISK children- Children under 1 year of age with a non-fused fontanel



Scheme 2b. Scheme of diagnostic and therapeutic procedures for head injury in MEDIUM RISK children- Children aged between 2 and 3 years

(depending on general condition of a child and mechanism of trauma) 12-24-48 hours

- Good general condition, no neurological symptoms, no signs of increased intracranial pressure - discharge to home
- Follow-up visit to a neurologist in 2-3 weeks
- Result of the ultrasound scan (-), but increasing anxiety, drowsiness during the observation, possible development of neurological disorders - a neurology consultation, follow-up transfontanelle ultrasound scan and/or CT of the head
- Results of the ultrasound scan (+) - CT of the head and a neurosurgery consultation.

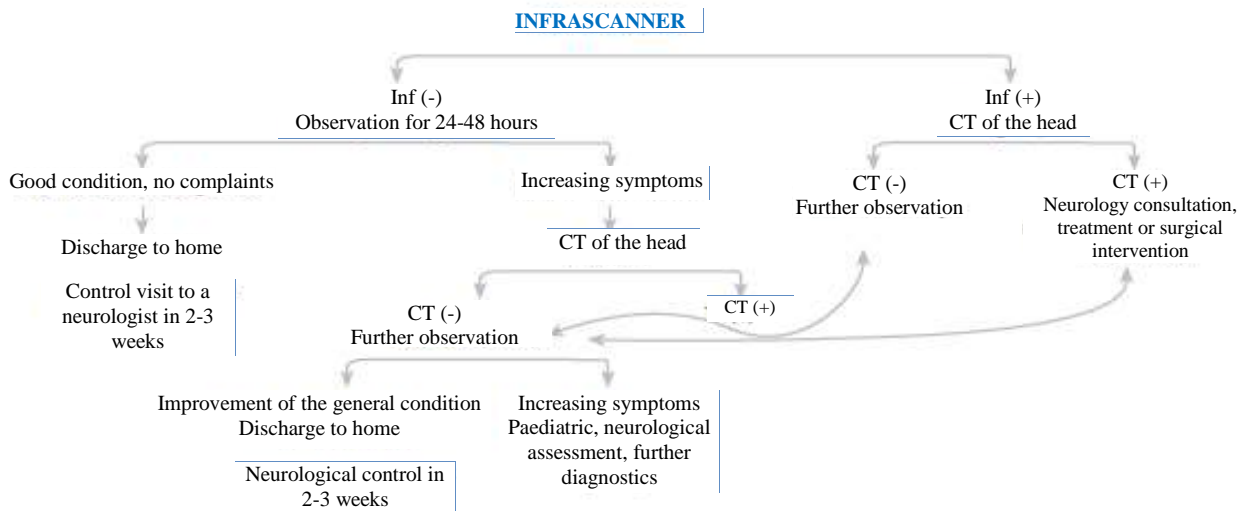
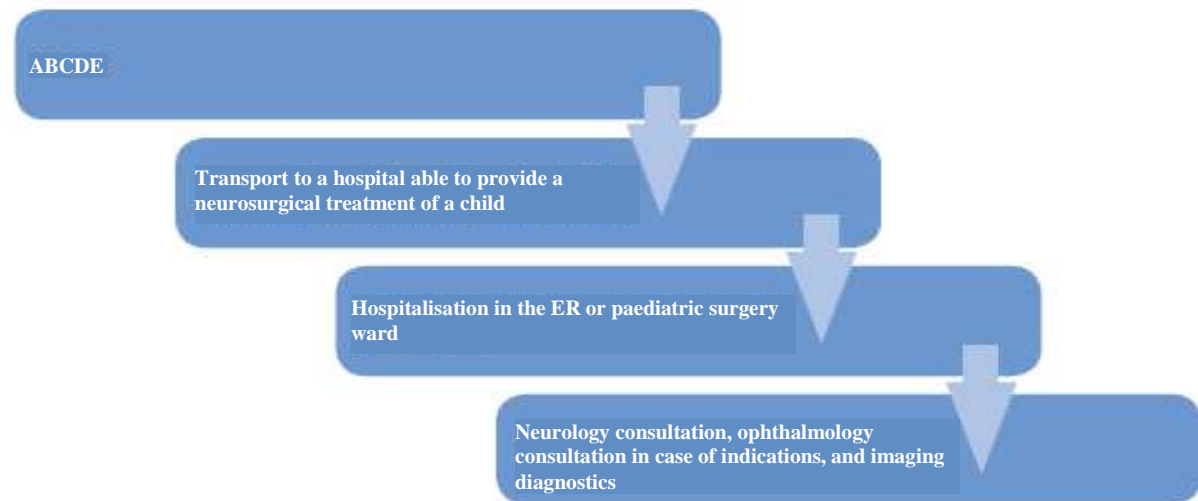
A child aged between 2 and 3 years

- Scheme 2b

- CT of the head CT (-) - inpatient observation for 24 - 48 hours
- During the inpatient observation the child's general condition good, the objective examination

performed by a paediatric surgeon indicates no neurological signs, including: positive meningeal signs - nuchal rigidity, signs of a focal injury of the CNS or signs indicating cranial nerve injury, no signs of increased intracranial pressure - discharge to home. Follow-up visit to a neurologist in 2-3 weeks

- CT (-) - during observation increasing anxiety, drowsiness, headaches and dizziness, persistent vomiting - a neurology consultation, paediatric assessment and possibly repeated CT
- CT (-) - further inpatient observation
- CT (+) - neurosurgery consultation, possible introduction of a treatment, including a surgical one.

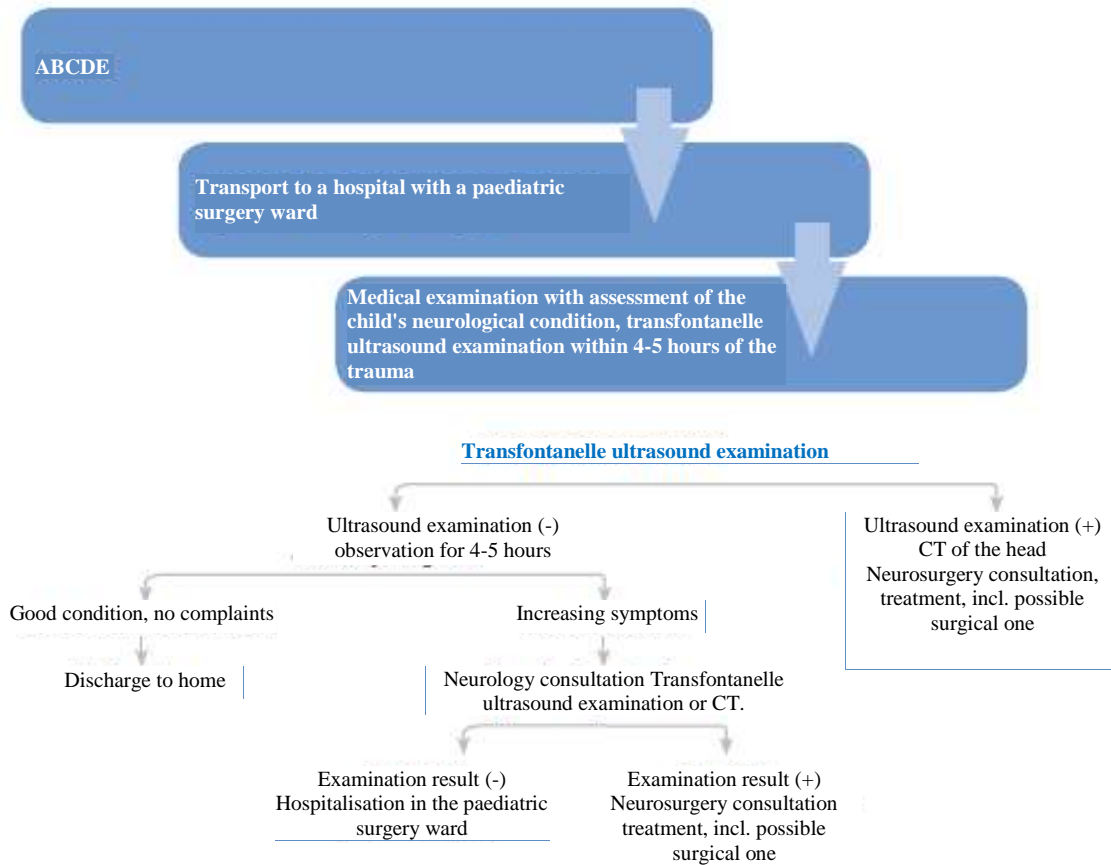


*Wards possessing no Infrascanner follow the scheme 2b

Scheme 2c. Scheme of diagnostic and therapeutic procedures for head injury in MEDIUM RISK children - Children >3 years of age

In case of a child aged > 3 years - Scheme 2c

- Wards possessing no Infrascanner and in case of children who do not meet the qualification criteria for Infrascanner examination - the procedure as defined under II.3b
- Wards possessing an Infrascanner and in case of children meeting criteria for Infrascanner examination - carry out the Infrascanner examination
- Infrascanner examination result (-) - inpatient observation for 24-48 hours. Good general condition, no neurological symptoms, no signs of increased intracranial pressure - discharge to home. A follow-up visit to a neurologist in 2-3 weeks
- Result of the Infrascanner examination (+) - CT of the head. If the result of CT (-) - inpatient observation for 24-48 hours
- If after the (-) CT of the head the patient's general condition is good, no neurological symptoms, no signs of increased intracranial pressure - discharge to home. Follow-up visit to a neurologist in 2-3 weeks
- If after the (-) CT of the head, increased anxiety, drowsiness, headaches and dizziness, and persistent vomiting are observed - neurology consultation and repeated Infrascanner examination (if available)
- Result of the Infrascanner examination (-) - further observation. No improvement or increasing clinical symptoms despite a negative result of the Infrascanner examination - necessary repeated CT of the head



Scheme 3a. Scheme of diagnostic and therapeutic procedures for head injury in LOW RISK Children - Children under 1 year of age with a non-fused fontanel

- If the result of a repeated CT (-) - paediatric assessment and neurological assessment
- If the result of a repeated CT (+) - neurosurgery consultation, possible introduction of a treatment, including a surgical one.

III. Low risk (regardless the child's age)

1. Assessment and management of basic life functions (ABCDE)
2. Transport to the nearest hospital with a paediatric surgery ward
3. Medical examination (with a precise history of the accident and the child's behaviour after the accident and medical history), with assessment of the child's neurological condition.

3a. In case of a child under 1 year of age and with non-fused fontanelle - Scheme 3a

- Observation at the ER for 4-5 hours, followed by a transfontanelle ultrasound examination. Result of the ultrasound scan (-) and good general condition of the patient, no subjective signs and symptoms - discharge for outpatient observation.

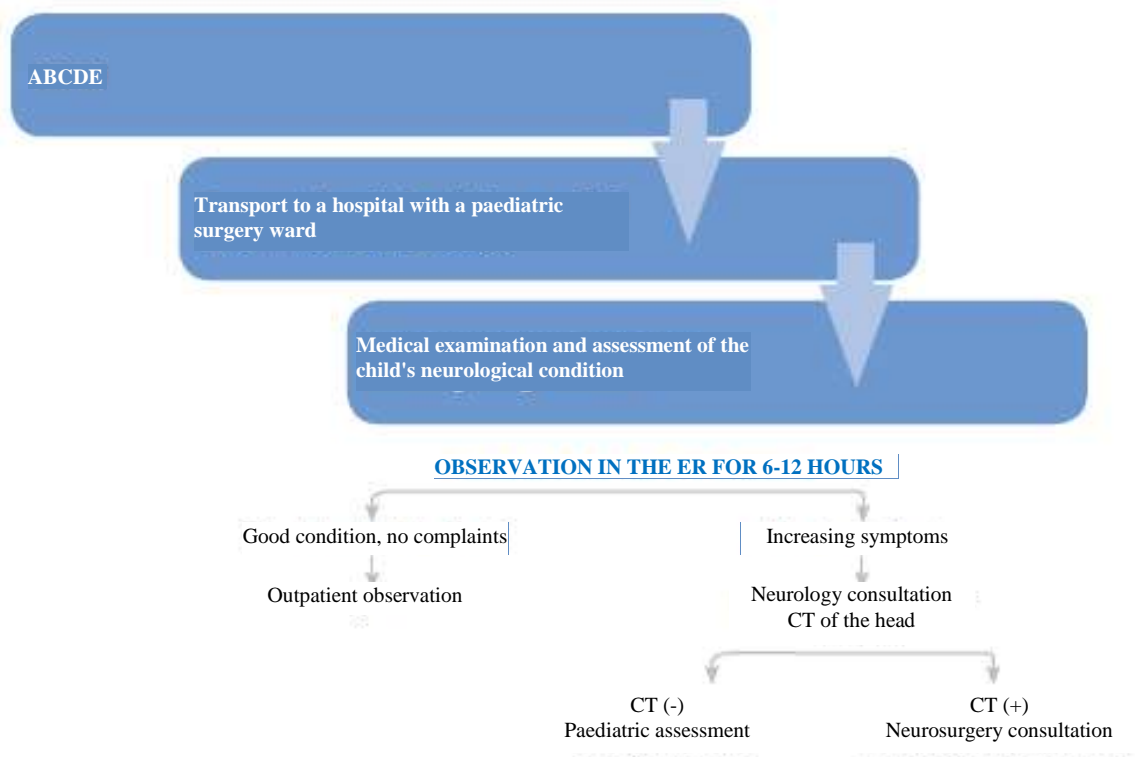
- Result of the ultrasound scan (-), but anxiety, drowsiness, vomiting or neurological signs appear during the observation period
- neurology consultation, follow-up transfontanelle ultrasound scan vs. CT of the head.

- Result of the repeated ultrasound scan (-) or CT (-) - hospitalisation in the paediatric surgery ward

- Result of the repeated ultrasound scan (+) - perform a CT of the head and a neurosurgery consultation, possible introduction of a treatment, including a surgical one.

3b. A child aged between 2 and 3 years - Scheme 3b

- Observation for 6-12 hours in the ER/paediatric surgery ward. Good general condition, no subjective signs or symptoms - a discharge for further outpatient observation. If anxiety, drowsiness, vomiting or neurological signs appear during the observation period - neurology consultation and CT of the head.



Scheme 3b. Scheme of diagnostic and therapeutic procedures for head injury in **LOW RISK Children- Children aged between 2 and 3 years**

- If the result of CT (-) - paediatric assessment
- If the result of CT (+) - neurosurgery consultation, possible introduction of a treatment, including a surgical one.

3c. In case of a child aged > 3 years - Scheme 3c

- Wards possessing no Infrascanner and in case of children who do not meet the qualification criteria for Infrascanner examination - the procedure as defined under I.3b
- Wards possessing an Infrascanner and in case of children meeting criteria for Infrascanner examination - carry out the Infrascanner examination
- Result of the Infrascanner examination (-) - good general condition, no neurological symptoms, no signs of increased intracranial pressure - discharge to home
- Result of the Infrascanner examination (+) - perform CT of the head
- Result of the CT of the head (-) - good general condition, no neurological symptoms, no signs of increased intracranial pressure
 - discharge to home. Result of the CT of the head (-)
 - increased anxiety, drowsiness, headaches and dizziness, and vomiting appear - neurology consultation and repeated Infrascanner examination.

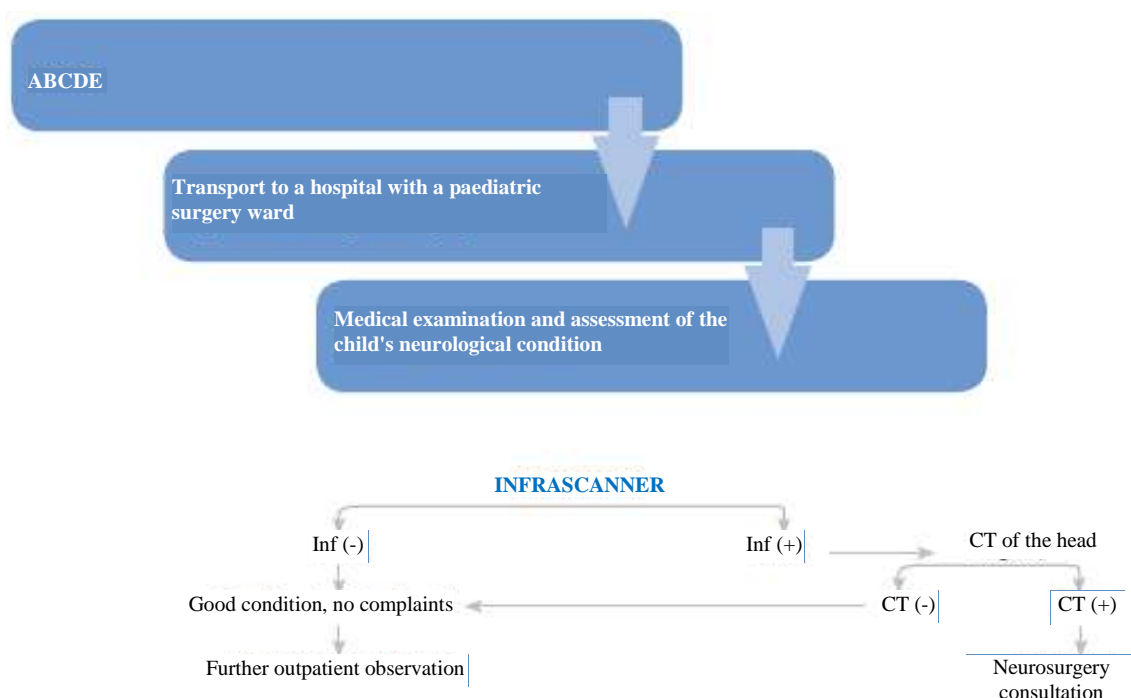
IV. Procedure in contused wounds of the head

- 1st Single wounds of the head, length of up to 5 cm, no bone injury, no loss of consciousness - cleaning, wound revision, suturing under local anaesthesia with 1% lidocaine
- 2nd Wound > 5 cm long, multiple wounds and single wounds of the head up to 5 cm long with a linear fracture of bone, or in a young child under the age of 3-4 years - cleaning, surgical debridement in a surgical suite in scope of a hospitalisation.

In the suggested scheme:

- 1st Current experience of foreign and home centres regarding treatment of minor and moderate head injuries has been taken into account
- 2nd No X-ray of the head in children with head injuries was applied, according to the general opinion of low usefulness of the diagnostic method
- 3rd Infrascanner examination was suggested as a basic examination in head injuries in children over the age of 3 years, according to reported high sensitivity of the method
- 4th CT and hospitalisation indications have been determined.

Implementation of those principles on the national level or at least in several centres for at least 2 years would allow their verification and further recommendation, or implementation of any possible modifications. ■



Scheme 3c Scheme of diagnostic and therapeutic procedures for head injury in **LOW RISK** children - **Children >3 years of age**

dr hab. n. med. Grażyna Skotnicka-Klonowicz



Oddział Kliniczny Medycyny Ratunkowej dla Dzieci Uniwersytecki Szpital Kliniczny nr 4 im. Marii Konopnickiej Uniwersytet Medyczny w Łodzi
91-738 Łódź, ul. Sporna 36/50

g.skotnicka@usk4.umed.lodz.pl

LITERATURE REFERENCES

1. Bałaj M. Minor Head Injury in Children - an Urgent Plea for Definition. *Advances in Clinical and Experimental Medicine* 2010;19:661-668
2. Radecka P, Kwiatkowski S, Milczarek O. Analiza wytycznych postępowania w lekkich i średnio ciężkich urazach głowy u nieletniej w latach 2002-2012. Czy istnieje możliwość ujednoczenia wskazań do wykonywania badań obrazowych. *Ostry Dyżur* 2013;6:99-104
3. Hilger T, Bałaj M, Zgierski J i wsp. Lekki uraz głowy u dzieci - propozycja algorytmu postępowania klinicznego. *Medycyna Wieku Rozwojowego* 2010;14:28-36
4. Bishop NB. Traumatic brain injury: a primer for primary care physicians. *Curr Probl Pediatr Adolesc Health* 2006;36:318-331
5. Dunning J, Daly J, Lomas J-P et al. Derivation of the children's head injury algorithm for the prediction of important clinical events decision rule for head injury in children. *Arch Dis Child* 2006;91:885-891
6. Falk P, Cederfjall C, Wendt I. Management and classification of children with head injury. *Child Nerv Syst* 2005;21:430-436
7. Bałaj M, Ładogórska J. Lekki uraz głowy u dzieci - czy badanie radiologiczne i hospitalizacja są konieczne w każdym przypadku. Badania ankietowe wśród chirurgów dziecięcych. *Przegląd Pediatryczny* 2007;37:100-105
8. Da Dalt L, Marchi AG, Laudizi L. Predictors of intracranial injuries in children after blunt head trauma. *Eur J Pediatr* 2006;165:142-148
9. Mc Kinlay A, Grace RC, Horwood LJ et al. Prevalence of traumatic brain injury among children adolescents and young adults: prospective evidence from a birth cohort. *Brain Inj* 2008;22:175-181
10. Crowe L, Anderson V, Babi FE. Application of the CHALICE clinical prediction rule for intracranial injury in children outside the UK: impact on head injury in children. *Arch Dis Child* 2010;95:1017-102
11. Kwiatkowski S.; Valenta M.; Grodzicka T.; Klauz G.; Grzegorzewski P.; Kawecki Z.: Algorytm postępowania w lekkich i średnio ciężkich urazach czaszkowo-mózgowych u dzieci. Rola konsultacji neurologicznej. *Neurologia Dziecięca* 2007, 16,31,13-16
12. Szwed -Białożył B.: Rola neurologa dziecięcego w diagnostyce urazów czaszkowo-mózgowych. *Neurologia Dziecięca* 2011.20, 39,71,-76-16
13. Stein S.; Doolin E.: Management of minor closed head injury in children and adolescents. *Ped Surg Int* 1995, 10, 465-471
14. Robertson CS.; Zager EL.; Narayan RK.; Handly N.; Sharama A.; Hanley DF.; Garza H.; Maloney-Wilensky E.; Plaum JM.; Koenig CH.; Johnson A.; Morgan T.: Clinical Evaluation of Portable Near-Infrared Device for Detection of Traumatic Intracranial Hematomas. *J Neurotrauma* 2010, 27,1597-1604
15. Schutzman SA, Barnes P, Duhaime AC, Greenes D, Homer C, Jaffe D, Lewis RJ, Luerssen TG, Schunk J: Evaluation and management of children younger than two years old with apparently minor head trauma: proposed guidelines. *Pediatrics*. 2001;107(5):983.

Appendix1. Glasgow Coma Scale (GCS)		
ASSESSED ACTIVITY	THE BEST RESPONSE	SCORE
Eye opening	Spontaneous	4
	To verbal stimuli	3
	To pain	2
	No reaction	1
Verbal response	Oriented	5
	Confused	4
	Improper words	3
	Incomprehensible sounds	2
	No reaction	1
Motor response	Follows orders	6
	Localises pain stimuli	5
	Withdrawal reaction to pain	4
	Flexion reaction to pain	3
	Extension reaction to pain	2
	No reaction	1

The modified Glasgow Scale for infants		
ASSESSED ACTIVITY	THE BEST RESPONSE	SCORE
Eye opening	Spontaneous	4
	To verbal stimuli	3
	To pain	2
	No reaction	1
Verbal response	Cooing	5
	Cries, restless	4
	Cry to pain stimuli	3
	Moans to pain stimuli	2
	No reaction	1
Motor response	Normal, spontaneous movements	6
	Abnormal flexion reaction	5
	Abnormal extension response	4
	Abnormal flexion reaction	3
	Abnormal extension response	2
	No reaction	1

16. Kuppermann N, Holmes JF, Dayan PS, Hoyle JD Jr, Atabaki SM, Holubkov R, Nadel FM, Monroe D, Stanley RM, Borgialli DA, Badawy MK, Schunk JE, Quayle KS, Mahajan P, Lichenstein R, Lillis KA, Tunik MG, Jacobs ES, Callahan JM, Gorelick MH, Glass TF, Lee LK, Bachman MC, Cooper A, Powell EC, Gerardi MJ, Melville KA, Muizelaar JP, Wisner DH, Zuspan SJ, Dean JM, Wootton-Gorges SL, Pediatric Emergency Care Applied Research Network (PECARN): Identification of children at very low risk of clinically-important brain injuries after head trauma: a prospective cohort study. *Lancet*. 2009;374(9696):1160.
17. Tang PH, Lim CC. Imaging of accidental paediatric head trauma. *Pediatr Radiol* 2009;39:438.
18. Leon-Carrion J, Dominguez-Roldan JM, Leon-Dominguez U, Murillo-Cabezas: The Infrascanner a handheld device for screening in situ for the presence of brain hematomas. *Brain Inf* 2010;24:1193-1201.
19. Bressan S, Daverio M, Martinolli F et al. The use of handheld near-infrared device (Infrascanner) for detecting intracranial haemorrhages in children with minor head injury. *Childs Nerv Syst* DOI10.1007/S00381-013-2314-2/ Published online 14 November 2013
20. Tyzo B, Trojanowski T, Szczepanek D, Rola R. Algorytm wstępnego postępowania w łagodnych urazach głowy z wykorzystaniem przenośnego spektroskopu bliskiej podczerwieni 2014;2:13-20.

Appendix 2 Qualification factors for Infrascanner examination

- age 4-18 years/in younger children there is a common technical problem associated with necessary application of the scanner to 4 symmetrical points/
- consciousness - GCS = 13-15
- loss of consciousness for less than 30 minutes
- no superficial injuries of the scalp in places to be examined with the Infrascanner
- no physical symptoms of cranial bone fracture
- patients with no neurological or neurosurgical history
- head injury not associated with a previous syncope
- children within 3 days of the trauma (because of haemolysis)